

## Review

# Management of short bowel syndrome in postoperative very low birth weight infants



Olivia Mayer <sup>a, \*</sup>, John A. Kerner <sup>a, b</sup>

<sup>a</sup> Lucile Packard Children's Hospital Stanford, Palo Alto, CA, USA

<sup>b</sup> Stanford University Medical Center, Stanford, CA, USA

## S U M M A R Y

### Keywords:

Very low birth weight infants  
Parenteral nutrition  
Short bowel syndrome  
Enteral nutrition  
Human milk  
Cholestasis  
Parenteral nutrition-associated cholestasis

Short bowel syndrome is a potentially devastating morbidity for the very low birth weight infant and family with a high risk for mortality. Prevention of injury to the intestine is the ideal, but, if and when the problem arises, it is important to have a systematic approach to manage nutrition, use pharmaceutical strategies and tools to maximize the outcome potential. Safely maximizing parenteral nutrition support by providing adequate macronutrients and micronutrients while minimizing its hepatotoxic effects is the initial postoperative strategy. As the infant stabilizes and starts to recover from that initial injury and/or surgery, a slow and closely monitored enteral nutrition approach should be initiated. Enteral feeds can be complemented with medications and supplements emerging as valuable clinical tools. Engaging a multidisciplinary team of neonatologists, gastroenterologists, pharmacists, skilled clinical nutrition support staff including registered dietitians and nutrition support nurses will facilitate optimizing each and every infant's long term result. Promoting intestinal rehabilitation and adaptation through evidence-based practice where it is found, and ongoing pursuit of research in this rare and devastating disease, is paramount in achieving optimal outcomes.

© 2016 Elsevier Ltd. All rights reserved.

## 1. Introduction

Infants with a birth weight of  $\leq 1500$  g are at high risk for a variety of morbidities including necrotizing enterocolitis (NEC), ischemic injury along the length of the intestine, jejunal or ileal atresias, and gastroschisis. All of these conditions may require surgical intervention. Short bowel syndrome (SBS) in very low birth weight (VLBW) infants, those born at  $\leq 1500$  g, continues to be an unfortunate reality and is the leading cause of intestinal failure in infants [1]. Outcomes vary, and are greatly influenced by age of the injury and potential for intestinal growth, the site of the resection, presence of the ileocecal valve (ICV), the development of parenteral nutrition-associated cholestasis [PNAC, also known as parenteral nutrition-associated liver disease (PNALD)], and functionality of the gastrointestinal (GI) tract [2,3]. Management of SBS can be extremely complicated and recovery may be lifelong for some. The medical journey is further confounded by other comorbidities of prematurity such as chronic lung disease, metabolic bone disease of

prematurity, extrauterine growth restriction, and congenital cardiac defects such as patent ductus arteriosus. A multidisciplinary team of neonatologists, gastroenterologists, surgeons, registered dietitians, nutrition support nurses, and pharmacists can enhance the prospect of achieving intestinal adaptation, appropriate growth and neurodevelopment [2,4].

Short bowel syndrome (SBS) is a state of malabsorption, and parenteral nutrition (PN) is needed for a prolonged period of time. Amin et al. define the need for PN as a minimum of three months whereas the Canadian Association of Pediatric Surgeons defines the need for PN as  $>42$  days [2,5]. From 2002 to 2005, surgical SBS was recorded in 0.7% of VLBW infants by the National Institute of Child Health and Development neonatal research network centers [6]. It is extremely difficult to accurately estimate the incidence and prevalence of SBS due to the rarity of the condition and the unclear and varied definitions used to describe not only the criteria but the outcomes. Ultra-short bowel has been defined by Diamanti et al. as  $\leq 10$  cm; by Gambarara et al. as  $\leq 20$  cm; and by De Greef et al. as  $\leq 40$  cm [7–9]. SBS is most frequently the result of a surgical resection of the bowel; however, even if adequate length and anatomy of the GI tract remain intact and well perfused, it may not function properly. Function of the bowel is just as, if not more,

\* Corresponding author. Address: Lucile Packard Children's Hospital Stanford, 750 Welch Road, Suite 214, Palo Alto, CA 94304, USA. Tel.: +1 650 497 8213.

E-mail address: [omayer@stanfordchildrens.org](mailto:omayer@stanfordchildrens.org) (O. Mayer).

important as the length of the remaining bowel. Critically decreased function below what is needed for adequate absorption of fluids, electrolytes, macro- and micronutrients results in intestinal failure [10]. It is possible for some patients to be discharged on full enteral nutrition; however, for those with intestinal failure, it is highly unlikely.

The leading cause of SBS in VLBW infants is NEC [6]. Other causes include, but are not limited to: spontaneous intestinal perforation, ileal/jejunal atresias, meconium plugs and/or obstruction, gastroschisis or other congenital malformation of the intestine, malrotation, volvulus, and intussusception. Congenital short bowel syndrome is a rare disorder whereby the length of the small intestine is much less than expected for age, and is hypothesized to have a genetic origin [11]. Data gathered from 2012 by Pant et al. highlight the epidemiology and healthcare resource utilization in the USA. The statistics reflect what most of us know from experience and observation. Children with SBS have a much higher rate of mortality, longer length of hospital stay, higher hospital costs, greater post-discharge needs and costs, and demonstrate more severe illness overall [12]. Complications frequently arise and include progressive liver dysfunction and disease, bacterial overgrowth, dysmotility, renal failure, venous access difficulties or loss, and catheter-related bloodstream infections [13]. Intestinal transplantation, with or without a combined liver transplantation, is a potential long-term intervention for those who suffer from chronic critical complications of PN dependence [10].

When an infant has undergone a surgical resection of the intestine, it is imperative to know exactly what parts of the intestine remain. The three most important elements to determine are whether the ICV remains intact, and the length and location of the remaining bowel. The ICV may slow transit time along the intestine and acts as a barrier to prevent bacterial translocation of colonic contents. It has been suggested that the ICV remaining intact reflects the abilities of the remaining terminal ileum [5]. The ileum absorbs fluid, vitamin B12, and bile acids, and if a significant section is removed, the jejunum has limited ability to adapt and develop some of the absorption abilities of the ileum [2]. Significant loss of the jejunum typically results in increased gastric emptying times and is associated with gastrin hypersecretion which may lead to fat malabsorption by inactivating pancreatic enzymes, acid-peptic injury, exacerbation fluid and electrolyte losses, and damage to the mucosa [2] (Fig. 1).

Premature infants have the greatest potential for intestinal growth and adaptation postoperatively. Intestinal adaptation can begin shortly after resection and lead to improved absorption of nutrients, fluids, and electrolytes. Intestinal adaptation drives overall intestinal rehabilitation by progressively attaining the ability to absorb and utilize all nutrition via an enteral route, without the need for PN support [5]. The length of the small bowel at 35 weeks of gestation is twice the length of the small bowel of a 19–27 week gestation [5]. Intestinal length can increase from  $142 \pm 22$  cm at 19–27 weeks to  $217 \pm 24$  cm at 27–35 weeks and to  $304 \pm 44$  cm at term age [14,15]. Over time, the intestine continues to grow up to 600–700 cm which may be reached by adulthood. There have been various findings and general observations of the bowel length and outcomes. It is generally postulated that, with  $\geq 15$  cm of remaining small intestine with an intact ICV, or 40 cm of small intestine without an ICV, a successful outcome is likely [16]. Demehri et al. found that presence of  $\geq 10\%$  expected small bowel length, an ICV, original diagnosis of NEC or atresia predicted weaning from PN [17]. To calculate the percent of expected bowel length, the authors measured the absolute length of remaining small bowel divided by the predicted length of small bowel based on the child's postconceptual age  $\times 100$  [17].

Intestinal proliferation, or lengthening of the villi, and to some degree dilatation of the small-bowel lumen, may result in increased mucosal surface area following massive resection and facilitate adaptation [10].

The clinical course of SBS patients has been described in three clinical stages: acute, recovery or intermediate, and a late phase in which PN is maintained with minimal metabolic effects and/or weaning from PN is possible [2,18]. The acute phase is the immediate time following the intestinal surgery. This phase can last up to 2–3 weeks post surgery and is focussed on managing the anticipated fluid, metabolic, and electrolyte fluctuations. The goal of the acute phase is to stabilize the infant, and nutrition is provided solely via PN. Concern for infection is great and the potential compounding effects on the liver from both PN and infection are prevalent. The recovery, or intermediate stage, is the time when enteral feedings are initiated and trialed, while PN continues to be the primary mode of nutrition. If an ostomy is present, the volume of output should be  $<40$  mL/kg/day [2,19]. Promoting age-appropriate growth, neurodevelopment, and bone mineralization are the ideal goals for premature infant nutrition; however, these goals may be relegated to a secondary role for a period of time if calories and lipids are restricted to minimize the deleterious effects of PN on the liver. The late clinical stage of SBS is when PN volume can be weaned down as the volume of enteral nutrition (EN) is advanced. The ultimate goal for these infants is to wean off PN completely. This late stage is to maximize EN volume, absorption, and overall tolerance, while minimizing PN volume, time, and hepatotoxic effects to promote growth, neurodevelopment, and prevent nutrient deficiencies.

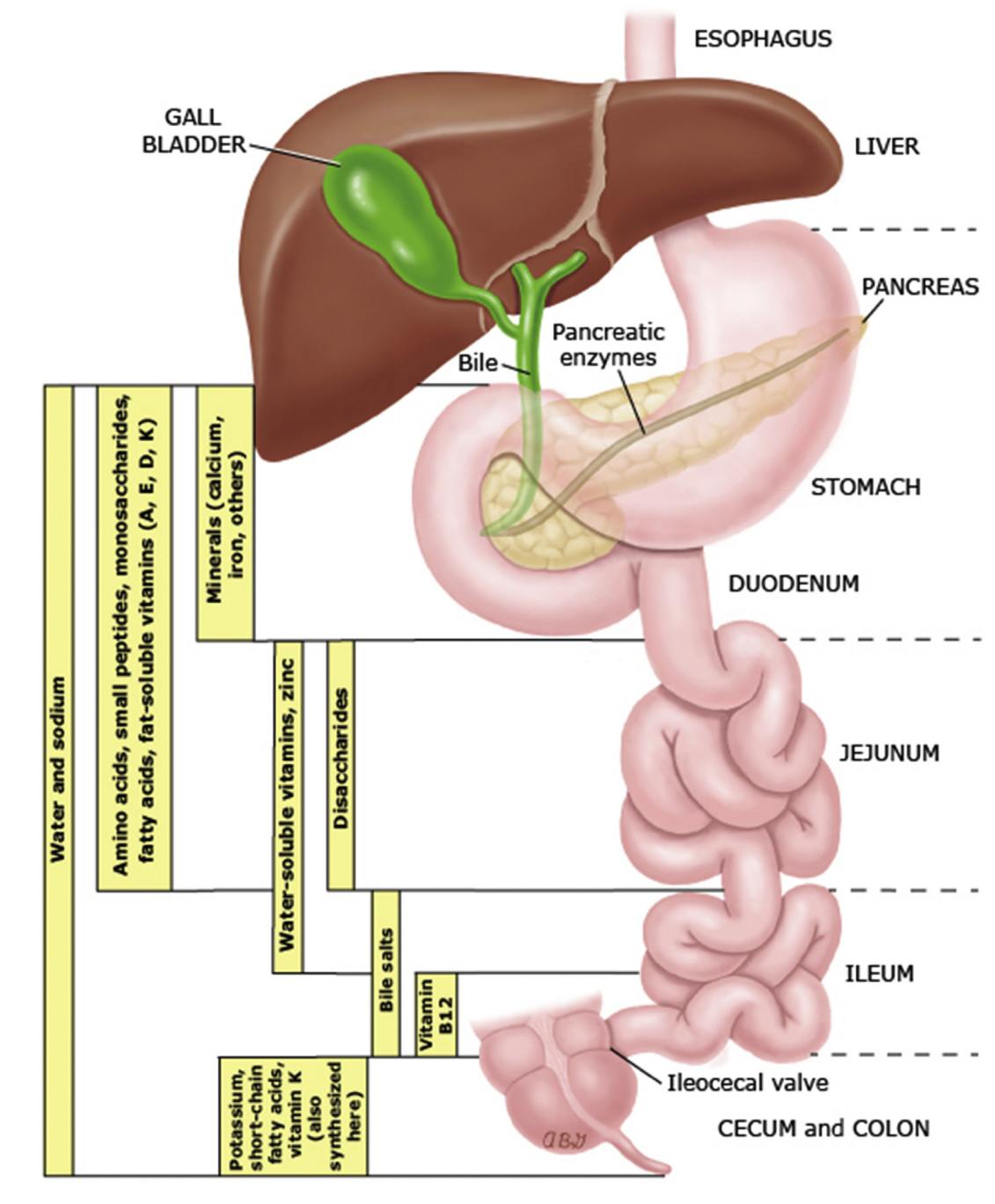
## 2. Parenteral nutrition strategies

Bypassing the GI tract to provide nutrition and fluids is life-saving in the management of SBS. Parenteral nutrition (PN) standards for VLBW infants promote growth, bone mineralization, and neurodevelopment. Infants dependent on prolonged PN are also at risk for macronutrient and micronutrient deficiencies. Balancing the need for good nutrition with the risks of prolonged PN is delicate and may be limited by vascular access issues, volume restrictions, product availability and manufacturing practices.

Ideal PN macronutrient needs for VLBW provides 90–100 kcal/kg/day, 4 g amino acids/kg/day, and 2.5–3 g fat/kg/day [20]. Frequent, standardized biochemical monitoring may be needed daily postoperatively as the infant is in the acute phase, for the first 2–5 days, but when greater metabolic stability has been achieved it may be monitored 1–2 days each week. Electrolyte and micronutrient imbalances often occur, and may need more frequent adjustment in the PN.

Prolonged duration of PN and lack of enteral feeds increases the infant's risk of developing cholestasis due to the hepatotoxic components used in PN solutions, overfeeding, soy-based intravenous (IV) lipid solutions, chronic infections, and decreased bile flow [21,22]. Delivering excessive macronutrients further exacerbates PNAC. High doses of intravenous dextrose have been shown to worsen PNAC more than IV lipids [21]. Gupta et al. found that limiting IV dextrose to a glucose infusion rate of  $\leq 9.3$  mg carbohydrate/kg/min in premature infants may be helpful in decreasing the incidence of PNAC [21]. Methionine excess from PN amino acids is also implicated in the development and exacerbation of PNAC [23]. IV lipids derived from soybean oil emulsions are frequently considered as the primary reason for cholestasis due to the effect of raising serum phytosterol concentrations which suppress bile flow, and providing  $\omega$ -6 fatty acids, which are pro-inflammatory [21,23–25]. For more than a decade, newer intravenous fat emulsions (IVFEs) have been produced that have been

## Intestinal sites of nutrient absorption



**Fig. 1.** Intestinal sites of nutrient absorption.

Reproduced with permission from DiBaise JK. Pathophysiology of short bowel syndrome. In: UpToDate, Post TW, UpToDate, Waltham MA, editors. (Accessed on 26/5/2016) Copyright © 2016 UpToDate, Inc. For more information visit [www.uptodate.com](http://www.uptodate.com).

shown to reverse and even to prevent the undesired outcome of PNAC [26]. In the USA the IVFE commercially dominant products are  $\omega$ -6 fatty acids. In most other areas of the world, novel IVFEs that contain a variable combination of  $\omega$ -6 and  $\omega$ -3 fatty acids, medium-chain triglycerides (MCTs), long-chain triglycerides, structured triglycerides, fish oil, and olive oil as sources have become standard of care [23,27]. Cessation of PN reduces and resolves chronic PNAC [28]. PN strategies used to minimize

neurologic and hepatic injury in VLBW SBS infants include using Trophamine<sup>®</sup> as the amino acid product, using the lowest aluminum-containing products, decreasing the glucose infusion rate, reducing or removal of trace elements, restricting IV lipid dose, using alternative IV lipid emulsions, cycling IV lipids and/or cycling PN administration [21,24,26,29]. Reducing or eliminating nutrients from the PN will put these infants at high risk for macro- and micronutrient deficiencies.

### 3. Enteral nutrition strategies

The ideal outcome for infants with SBS is to thrive on enteral nutrition alone. VLBW infants are at an initial disadvantage for excellent feeding tolerance and growth due to the immaturity of the GI tract and other metabolic and immunologic complications of prematurity. SBS further compounds this struggle. Prolonged periods of time during which the GI tract is not stimulated by enteral nutrition lead to loss of structural formation of tight junctions, and deterioration of epithelial barrier function which further increases one's risk of infection and inflammation [30]. Lack of EN and antibiotic use showed a greater influence than surgery on altering the diversity of the intestinal microbiome in a piglet model of intestinal failure [31].

Delivery of enteral nutrition is often debated in this population due to the somewhat inconclusive evidence, personal preference and experience of the practitioner. Gastric feeds are the first choice, and may be the only option if the jejunum has been resected. If an infant has a jejunostomy in place, bear in mind this further increases the risk of introducing contaminants into the small bowel which may result in small bowel bacterial overgrowth or sepsis [3]. In VLBW infants without SBS, the evidence shows that both continuous and bolus feeding strategies are suitable with their own set of risks and benefits [32,33]. Whereas bolus or intermittent feeding may result in a more physiological hormonal response, improved motility, and possibly enhanced protein accretion, bolus feeds may result in increased feeding intolerance such as emesis, firm abdomen, increase in abdominal circumference and feeding-related apneas or desaturations [32]. Using gastric residual volume as a marker for intolerance is no longer evidence-based [32]. If a portion of the intestine has been removed, the remaining intestine may be overwhelmed not only by volume, but the osmolality, and adverse events, such as emesis, diarrhea, copious ostomy output, or intestinal perforation may result. Continuous or semi-continuous feeding may improve nutrient absorption, duodenal motor function, energy efficiency, and splanchnic oxygenation [10,32].

In SBS continuous feeds optimize absorption (and probably adaptation) by permitting total saturation of the transporters in the gut for 24 h/day. Enteral nutrition in SBS is usually started slowly and advanced based on stool or ostomy output (and other abdominal symptoms and signs) [5]. Initially, enteral feeding tolerance should be the primary focus in SBS infants to commence the intestinal adaptation process. Starting with trophic volumes of ~10 mL/kg/day given as 1–2 mL Q 3–6 h for 24–48 h is reasonable to assess initial tolerance and to identify possible strictures or postoperative ileus. Trophic feeds should be seen as 'medicinal' or 'therapeutic', not as a source of nutrition. As enteral feeding tolerance is demonstrated, a slow and closely monitored feeding advancement can be initiated. Typically, feeding volume is advanced by 20–30 mL/kg/day; however, for the VLBW SBS infant, initial advancement of feeds may be as slow as increasing by 1 mL every 24 h. Once the infant is tolerating at least 50–60 mL/kg/day, the advancement of feeds may be able to quicken, again, depending on the infant's clinical picture.

Higher volumes of ostomy output typically have a negative effect on hydration status, electrolyte stability, and weight gain/growth. Conventional wisdom is that ideal ostomy output volume should be <40 mL/kg/day [2,19]. If the ostomy output is >40 mL/kg/day and the infant is gaining weight and metabolically stable, then perhaps it is fine to accept a higher output volume and continue to monitor very closely for dehydration and electrolyte alterations. More often, when ostomy output is >40 mL/kg/day, the infant is more likely to become dehydrated and experience

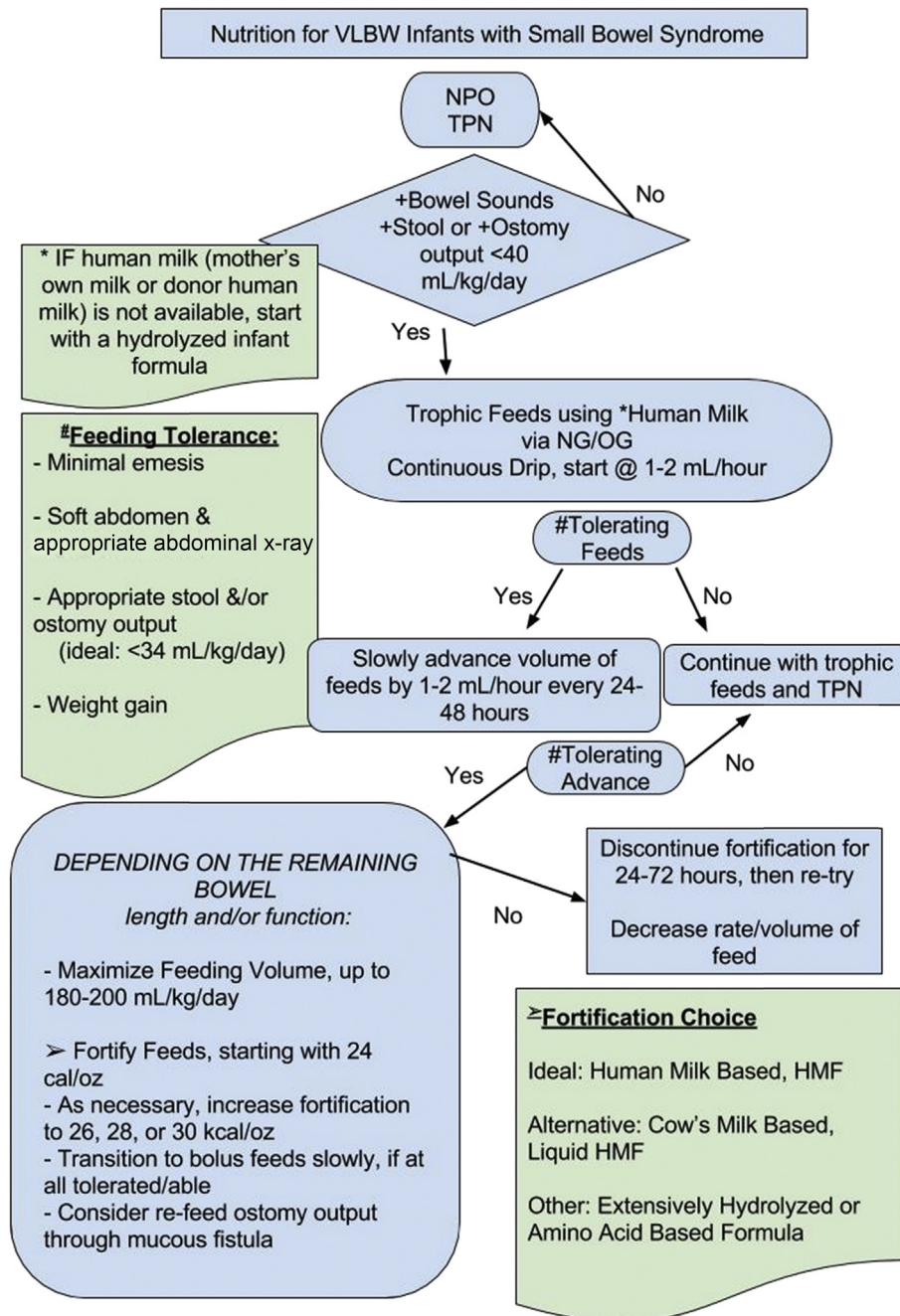
electrolyte abnormalities. Regardless of the ostomy output volume, if infants are not growing, they are not absorbing all the nutrients they need from the feeds. Assessing ostomy output for malabsorption, by checking a fat stain, pH, and reducing substances may guide your feeding choice. Refeeding enterostomy output through a mucous fistula has been shown to facilitate improved growth and improved EN tolerance after the bowel has been reconnected [34–37]. As with all invasive therapies, refeeding is not without risk and may lead to further complications such as perforation, intestinal bleeding, death, and ongoing PN dependence [38].

Human milk is the preferred nutrition choice for all infants, and the benefits far outweigh any perceived risks when fed to premature infants [39]. Mother's own milk is ideal; however, if it is not available, donor human milk should be the alternative. Human milk contains properties that are non-replicable and provides advantages that infant formula cannot, such as protection from PNALD in those who receive PN >4 weeks [40]. It is reasonable to achieve full volume enteral feeds before adding fortification in order to minimize variables as EN progresses. When combined with human milk, human milk-based fortifiers will allow the infant to receive an exclusive human milk diet that meets their estimated high nutrition needs, appropriately stimulate and promote trophic effects such as maturation, motility, and decrease permeability; while additionally receiving immunologic components to aid their immature immune system [41,42]. When human milk-based fortifiers are not available, then a cow's milk-based liquid formulation of human milk fortifier (HMF) should be used to meet the high nutrition needs.

If human milk is not available or tolerated, standard, intact cow's milk protein-based formulas should be tried first [18]. Allergic reactions to cow's milk protein and soy protein are widespread. If standard formulas are poorly tolerated, trying a partially or extensively hydrolyzed protein formula should be the next step. Hydrolyzed formulas have been shown to improve gastric emptying time as well as improve nitrogen retention by increasing serum amino acid concentrations, and most provide a higher percentage of its fat from medium chain triglycerides (MCT) [43]. Finally, if all other formulas and feeding strategies fail, try a free amino acid-based formula. These have been associated with a shorter duration of PN, decreased risk of developing a food allergy, and are generally well tolerated, despite their higher osmolality [44] (Fig. 2).

Formulas with >40% of its total fat from MCTs are preferred due to ease of absorption directly into the portal system, without the need for bile acids and micelles. Increased absorption and retention of fat leads to improved weight gain and growth. Fatty acids metabolized to short-chains have been shown to have trophic effects and aid with adaptation and absorption in both the small bowel and colon. Fat intake for VLBW is incredibly important, not just for somatic growth, but also for brain growth and development. Polyunsaturated fatty acid intake, especially docosahexaenoic acid (DHA) and arachidonic acid (ARA), is strongly correlated with positive cognitive effects in the short term; however, a recent study showed no cognitive or structural advantage to feeding VLBW infants DHA- and ARA-supplemented formula at 8 years of age [45].

Enteral nutrition strategies continue to evolve. Feeding options derived from human milk and enteral formulas striving to replicate human milk continue to emerge. Vitamin and mineral supplementation to meet micronutrient needs are standard therapy. Controversy surrounds supplemental enteral glutamine, though it has been used for years on the premise that it will aid in decreased intestinal permeability, improved tolerance to enteral feeds,



**Fig. 2.** Decision tree guidelines for enteral nutrition in VLBW SBS infants post-surgical resection. HMF, Human Milk Fortifier; NPO, nothing by mouth; NG, Nasogastric Tube; OG, Orogastric Tube; TPN, Total Parenteral Nutrition.

improved growth, and immune function support [46]. Probiotics – a promising therapy in GI tract colonization, downregulation of proinflammatory response, feeding tolerance, and growth – still pose a risk for bacterial overgrowth and sepsis in those infants with IV lines in place [47]. *Lactobacillus* bacteremia and *Saccharomyces boulardii* fungemia have been reported in SBS patients with a central venous catheter [18].

Prebiotics are a non-digestible food ingredient that has a beneficial effect on the body. Prebiotics stimulate growth of, or activity of, bacteria found in the colon that promote good gut health [48]. Human milk oligosaccharide 2'-fucosyllactose (a prebiotic) supplementation has had promising results promoting intestinal

adaptation in the murine model that showed improved weight gain, increased microbial diversity after resection, and improved energy processing [49]. Stimulation of enteroplasticity in the distal intestine is improved by prebiotics by increasing glucose and glutamine transport in the jejunum.

Lactoferrin (LF) is an anti-infective component found in whey protein in all mammalian milk and promotes GI function by decreasing permeability, which decreases the risk of colonization by pathogens and decreasing infections. Human milk is a rich source of LF. Cow's milk LF can be isolated and produced as a supplement. Research continues to explore a potential role for supplementation [50].

For those infants who develop PNAC, as they begin to tolerate some enteral nutrition, providing enteral fish oil supplementation may not only provide additional calories and enhance enteral feeding tolerance, it may also promote the reversal of PNAC and demonstrate improvement in liver function tests [51–54]. Based on the initial finding that administering a fish-oil based IVFE resulted in improved liver function tests (LFT), for those infants suffering from SBS and facing prolonged PN dependence who are able to tolerate EN, enteral fish oil supplementation is a more readily available, economically sound, and physiologically beneficial therapy by reducing the inflammatory response in the GI tract and the liver [54].

#### 4. Pharmaceutical strategies

Pharmaceutical therapies continue to be developed. Many infants will need sustained electrolyte, vitamin, and mineral supplementation as long as they still have an ostomy in place. Hypersecretion of gastric acid, a frequent postoperative challenge, may reduce the pH below the level needed for efficient fat malabsorption and may lead to peptic complications. The use of acid-suppressing medications such as proton pump inhibitors and H<sub>2</sub> blockers is required during the first six months to one year following resection. Chronic use of acid suppressants will raise the pH of the stomach, which may increase the risk of viral infections and the risk of bacterial overgrowth [10]. Medications used to slow motility such as loperamide (Imodium) are a therapy used most widely in those with excessive fluid losses in stool or high volume ostomy output in older infants and children; however, such agents should be used with great caution in those who are prone to small-bowel bacterial overgrowth [10]. Given the high risk for infections from central intravenous lines, especially in patients with small-bowel bacterial overgrowth, and an immature immune system, broad-spectrum antibiotics are often used when an infant presents with fever until a specific sensitivity can be determined for targeted antibiotic therapy [10]. The use of ethanol lock therapy is increasingly being used as a long-term strategy to further lessen the risk of catheter-related bloodstream infections, which may be life-threatening in these patients [10,55]. Studies to date have only documented safety and benefit of ethanol lock therapy in infants >5 kg. Long-term care of the central line is critical to the ability to provide nutrition and appropriate medications to the patient. Standardized, evidence-based practice of flushing protocols should be utilized to prevent line occlusion, and use of thrombolytic agents should be used to restore patency [10].

Intestinal dysmotility may occur in many infants with SBS. Erythromycin increases gut motility by activating motilin receptors [2]. In a recent review, erythromycin use was associated with shorter time to full feeds, decreased duration of parenteral nutrition, and decreased incidence of cholestasis [56]. Its use was in preterm infants but not those with SBS.

Ursodeoxycholic acid (UDCA) is frequently used for the treatment of PNAC. Most studies are in premature infants with an intact intestinal tract. UDCA is usually given at a dose of 20–30 mg/kg/day divided in two or three doses once patients are tolerating EN. However, it may be poorly absorbed in patients with no ileum or with significant intestinal failure, causing more diarrhea. Gallbladder stasis is from lack of enteral feedings, and a reduction of bile salts may lead to the formation of cholesterol stones. UDCA therapy is clearly recommended in this group. Early cholecystectomy for cholelithiasis should be considered.

Many novel therapies have been proposed to improve bowel adaptation. Animal models have evaluated epidermal growth factor (EGF), growth hormone (GH), glucagon-like-peptide 2 (GLP-2), keratinocyte growth factor, interleukin-II, and basic fibroblast

growth factor [2,57]. The GLP-2 analog (teduglutide), EGF, GH, and oral insulin supplementation are the only products assessed so far in humans.

Teduglutide (Gattex) has been approved by the US Food and Drug Administration (FDA) for use in adults with SBS. It has been shown to reduce the need for parenteral nutrition by more than 20% in double-blind randomized adult human trials. Teduglutide induced an increase in plasma citrulline, a marker for enterocyte mass, implicating a healthy reparative effect on the remaining intestinal mucosa of adult patients [58]. Of the 173 patients who received teduglutide in the two phase III clinical trials, seven patients achieved complete independence from PN and/or intravenous fluids [59]. Finally, a pediatric trial of teduglutide is currently underway.

Enteral EGF has been studied in pediatric patients with SBS [60]. Five SBS patients had improved nutrient absorption and increased tolerance with enteral feeds. No study yet has demonstrated that EGF has shortened the duration of PN significantly.

Growth hormone is approved in the USA in adults with SBS. Goulet et al. [18] described his own study of high-dose recombinant human growth hormone (rhGH) which allowed PN to be decreased in children with SBS, probably resulting from a significant increase in oral intake as well as net energy and fluid balances. However, the effects of rhGH were not sustained after discontinuation of the treatment for most of the children. They cited a study by Peretti et al. that showed no benefit of rhGH [61].

Finally, a pilot observational study of oral insulin supplementation to pediatric SBS patients resulted in clinical improvement in a subset of patients [61]. Nutrinia has been granted FDA Orphan Designation for NTRA-9620 for SBS. The company is launching a US and European multinational study in neonatal SBS patients to begin late 2016/early 2017. The active ingredient is insulin, which is known to play a key role in maturation and rehabilitation of the GI tract.

#### 5. Laboratory monitoring

In the acute phase – those first two weeks or so, of the initial intestinal injury – it is vital to closely monitor complete blood counts, electrolytes, renal function, blood glucose, and serum triglycerides. It may be necessary to check electrolytes more than once each day to ensure that they remain within normal limits as much as possible given the physiological response post surgery. Renal function may become impaired, hyperglycemia and hypertriglyceridemia may rise due to an inflammatory state or immature metabolism. An upward trend in liver function tests foreshadows dysfunction, exposing evidence of hepatic injury and chronic inflammation. Serum conjugated bilirubin >2 mg/dL after an infant has been on PN for >2 weeks is the usual diagnostic marker for diagnosis of PNAC [21]. As the infant becomes stable and transitions to the recovery or intermediate stage, laboratory monitoring may be decreased to obtaining them no more than two or three times per week, like any other standard PN patient.

Close monitoring of serum zinc, copper, and selenium monthly will help to minimize the potential effects of deficiency such as poor growth, metabolic bone disease, and cardiomyopathy. Monitoring for essential fatty acid deficiency will vary depending on the dose of IVFE, EN, and degree of malabsorption. Measuring fat soluble vitamins A, D, E, and K are important and may be checked every 1, 3, or 6 months, as needed. More frequent monitoring should occur to check for repletion if found to be insufficient/deficient. If the infant develops increased ostomy output, or more frequent loose stools, and is at risk for dehydration, then more frequent electrolyte monitoring is warranted. This stage of recovery might endure for weeks, months, or even years into the late phase of SBS.

Following serum citrulline levels is now widely performed in infants who develop IF to use as a marker for small bowel length, small bowel absorption capabilities, and prognosis for weaning from PN [62–64]. Serum citrulline >19  $\mu\text{mol/L}$  is associated with enteral nutrition tolerance and the ability to be weaned off PN [63].

Short bowel syndrome is a potentially devastating morbidity for the VLBW infant and family with a high risk for mortality. Prevention of injury to the intestine is the ideal, but if and when the problem arises, it is important to have a systematic approach to manage nutrition, and use pharmaceutical strategies and tools to maximize the outcome potential. Safely maximizing PN support by providing adequate macronutrients and micronutrients while minimizing its hepatotoxic effects is the initial postoperative strategy. As the infant stabilizes and starts to recover from that initial injury and/or surgery, a slow and closely monitored enteral nutrition approach should be initiated. Enteral feeds may be complemented with medications and supplements emerging as valuable clinical tools. Engaging a multidisciplinary team of neonatologists, gastroenterologists, pharmacists, skilled clinical nutrition support staff including registered dietitians and nutrition support nurses will facilitate optimizing each and every infant's result. Future care of the VLBW SBS infant may include developing innovative surgical techniques, less hepatotoxic medications, and possibly the production of an artificial intestine for management of SBS or perhaps to replace intestinal transplants [65]. Promoting intestinal rehabilitation and adaptation through evidence-based practice where it is found, and ongoing pursuit of research in this rare and devastating disease, is paramount in achieving optimal outcomes.

### Practice points

- Engage a multidisciplinary team of neonatologists, gastroenterologists, pharmacists, skilled clinical nutrition support staff including registered dietitians and nutrition support nurses will facilitate optimizing each and every infant's outcome.
- It is imperative to know the length of the remaining bowel, what segments remain, and if the ICV remains intact. Having that knowledge will help to better understand the infant's potential for intestinal growth, potential for absorption, and guide the medical nutrition therapy.
- Provide parenteral nutrition that supports growth and implement strategies to delay, if not prevent, PNAC. Strategies include reducing IV lipid dose, using alternative IV lipids, decreasing the GIR, and reduce or withdraw hepatotoxic micronutrients.
- Enteral nutrition is started as soon as medically safe, and mother's own milk (or donor human milk) is the ideal source of nutrition. Enteral feeds will need to be fortified to meet the very high nutritional demands of VLBW infants.
- Many infants are at risk for essential fatty acid and micronutrient deficiencies and may need sustained electrolyte, vitamin, and mineral supplementation.
- In general, infants will be treated with gastric acid suppression medications, motility agents, antibiotics, and ursodeoxycholic acid. The use of these medications, although typically universal, will vary depending on the infant's course of intestinal rehabilitation.

### Research directions

- Further research should investigate and potentially create alternative parenteral nutrition products made from less toxic components.
- Further exploration in developing alternative enteral nutrition products and formulas that are derived from human milk, or more closely resemble human milk, and enhance intestinal rehabilitation and overall growth.
- Further research into pharmaceutical products and interventions that compliment enteral nutrition therapy.

### Conflict of interest statement

Olivia Mayer has received speaker honoraria from ProLacta Bioscience, Inc.

### Funding sources

None.

### References

- [1] Squires RH, Duggan C, Teitelbaum DH, et al. Natural history of pediatric intestinal failure: initial report from the Pediatric Intestinal Failure Consortium. *J Pediatr* 2012;161:72–8. e722.
- [2] Amin SC, Pappas C, Iyengar H, Maheshwari A. Short bowel syndrome in the NICU. *Clin Perinatol* 2013;40:53–68.
- [3] Goulet O. 3.9 Malabsorptive disorders and short bowel syndrome. *World Rev Nutr Diet* 2015;113:182–9.
- [4] Merras-Salmio L, Pakarinen MP. Refined multidisciplinary protocol-based approach to short bowel syndrome improves outcomes. *J Pediatr Gastroenterol Nutr* 2015;61:24–9.
- [5] Goday PS. Short bowel syndrome: how short is too short? *Clin Perinatol* 2009;36:101–10.
- [6] Cole CR, Hansen NI, Higgins RD, Ziegler TR, Stoll BJ. Very low birth weight preterm infants with surgical short bowel syndrome: incidence, morbidity and mortality, and growth outcomes at 18 to 22 months. *Pediatrics* 2008;122:e573–82.
- [7] Diamanti A, Conforti A, Panetta F, et al. Long-term outcome of home parenteral nutrition in patients with ultra-short bowel syndrome. *J Pediatr Gastroenterol Nutr* 2014;58:438–42.
- [8] Gambarara M, Ferretti F, Bagolan P, et al. Ultra-short-bowel syndrome is not an absolute indication to small-bowel transplantation in childhood. *Eur J Pediatr Surg* 1999;9:267–70.
- [9] De Greef E, Mahler T, Janssen A, Cuypers H, Veereman-Wauters G. The influence of neocate in paediatric short bowel syndrome on PN weaning. *J Nutr Metab* 2010. pii: 297575.
- [10] Vanderhoof JA, Pauley-Hunter R. Short bowel syndrome. In: *Textbook of pediatric gastroenterology, hepatology, and nutrition*. Basel: Springer; 2016. p. 495–503. Ch 43.
- [11] van der Werf CS, Halim D, Verheij JB, Alves MM, Hofstra RM. Congenital short bowel syndrome: from clinical and genetic diagnosis to the molecular mechanisms involved in intestinal elongation. *Biochim Biophys Acta* 2015;1852:2352–61.
- [12] Pant C, Sferra TJ, Fischer RT, Olyae M, Gilroy R. Epidemiology and healthcare resource utilization associated with children with short bowel syndrome in the United States. *J Parenter Enteral Nutr* 2015 October 30 [Epub ahead of print].
- [13] Kaufman SS, Matsumoto CS. Management of pediatric intestinal failure. *Minerva Pediatr* 2015;67:321–40.
- [14] Struijs MC, Diamond IR, de Silva N, Wales PW. Establishing norms for intestinal length in children. *J Pediatr Surg* 2009;44:933–8.
- [15] Touloukian RJ, Smith GJ. Normal intestinal length in preterm infants. *J Pediatr Surg* 1983;18:720–3.
- [16] Wilmore DW. Factors correlating with a successful outcome following extensive intestinal resection in newborn infants. *J Pediatr* 1972;80:88–95.
- [17] Demehri FR, Stephens L, Herrman E, et al. Enteral autonomy in pediatric short bowel syndrome: predictive factors one year after diagnosis. *J Pediatr Surg* 2015;50:131–5.
- [18] Goulet O, Olieman J, Ksiazyk J, et al. Neonatal short bowel syndrome as a model of intestinal failure: physiological background for enteral feeding. *Clin Nutr* 2013;32:162–71.

- [19] Wessel JJ, Kocoshis SA. Nutritional management of infants with short bowel syndrome. *Semin Perinatol* 2007;31:104–11.
- [20] Corkins MR, Balint J, Bobo E, Plogsted S, Yaworski JA, editors. *The ASPEN Pediatric Nutrition Support Core Curriculum*. 2nd ed. American Society for Parenteral and Enteral Nutrition; 2015. p. 594–6.
- [21] Gupta K, Wang H, Amin SB. Parenteral nutrition-associated cholestasis in premature infants: role of macronutrients. *J Parenter Enteral Nutr* 2016;40:335–41.
- [22] Beath SV, Kelly DA. Total parenteral nutrition-induced cholestasis: prevention and management. *Clin Liver Dis* 2016;20:159–76.
- [23] Diamond IR, Wales PW. Advantages of the distal sigmoid colostomy in the management of infants with short bowel syndrome. *J Pediatr Surg* 2008;43:1464–7.
- [24] Levit OL, Calkins KL, Gibson LC, et al. Low-dose intravenous soybean oil emulsion for prevention of cholestasis in preterm neonates. *J Parenter Enteral Nutr* 2016;40:374–82.
- [25] Gura KM, Lee S, Valim C, et al. Safety and efficacy of a fish-oil-based fat emulsion in the treatment of parenteral nutrition-associated liver disease. *Pediatrics* 2008;121:e678–86.
- [26] Goulet OJ. Intestinal failure-associated liver disease and the use of fish oil-based lipid emulsions. *World Rev Nutr Diet* 2015;112:90–114.
- [27] Hippalgaonkar K, Majumdar S, Kansara V. Injectable lipid emulsions – advancements, opportunities and challenges. *AAPS Pharm Sci Tech* 2010;11:1526–40.
- [28] Adaba F, Uppara M, Iqbal F, et al. Chronic cholestasis in patients on parenteral nutrition: the influence of restoring bowel continuity after mesenteric infarction. *Eur J Clin Nutr* 2016;70:189–93.
- [29] Poole RL, Pieroni KP, Gaskari S, Dixon T, Kerner JA. Aluminum exposure in neonatal patients using the least contaminated parenteral nutrition solution products. *Nutrients* 2012;4:1566–74.
- [30] Ralls MW, Demehri FR, Feng Y, Woods Ignatoski KM, Teitelbaum DH. Enteral nutrient deprivation in patients leads to a loss of intestinal epithelial barrier function. *Surgery* 2015;157:732–42.
- [31] Levesque CL, Turner J, Li J, et al. In a neonatal piglet model of intestinal failure, administration of antibiotics and lack of enteral nutrition have a greater impact on intestinal microflora than surgical resection alone. *J Parenter Enteral Nutr* 2016 Feb 2 [Epub ahead of print].
- [32] Rövekamp-Abels LW, Hogewind-Schoonenboom JE, de Wijs-Meijler DP, et al. Intermittent bolus or semicontinuous feeding for preterm infants? *J Pediatr Gastroenterol Nutr* 2015;61:659–64.
- [33] Premji SS, Chessell L. Continuous nasogastric milk feeding versus intermittent bolus milk feeding for premature infants less than 1500 grams. *Cochrane Database Syst Rev* 2011;(11):CD001819.
- [34] Inoue S, Odaka A, Muta Y, Beck Y, Sobajima H, Tamura M. Recycling small intestinal contents from proximal ileostomy in low birth weight infants with small bowel perforation: retrospective case series. *J Pediatr Gastroenterol Nutr* 2014;22:22.
- [35] Koike Y, Uchida K, Nagano Y, et al. Enteral refeeding is useful for promoting growth in neonates with enterostomy before stoma closure. *J Pediatr Surg* 2016;51:390–4.
- [36] Gardner VA, Walton JM, Chessell L. A case study utilizing an enteral refeeding technique in a premature infant with short bowel syndrome. *Adv Neonatal Care* 2003;3:258–68. quiz 269–71.
- [37] Wong KK, Lan LC, Lin SC, Chan AW, Tam PK. Mucous fistula refeeding in premature neonates with enterostomies. *J Pediatr Gastroenterol Nutr* 2004;39:43–5.
- [38] Haddock CA, Stanger JD, Albersheim SG, Casey LM, Butterworth SA. Mucous fistula refeeding in neonates with enterostomies. *J Pediatr Surg* 2015;50:779–82.
- [39] Moro GE, Arslanoglu S, Bertino E, et al. XII. Human milk in feeding premature infants: consensus statement. *J Pediatr Gastroenterol Nutr* 2015;61(Suppl. 1):S16–9.
- [40] Kulkarni S, Mercado V, Rios M, et al. Breast milk is better than formula milk in preventing parenteral nutrition-associated liver disease in infants receiving prolonged parenteral nutrition. *J Pediatr Gastroenterol Nutr* 2013;57:383–8.
- [41] Abrams SA, Schanler RJ, Lee ML, Rechtman DJ. Greater mortality and morbidity in extremely preterm infants fed a diet containing cow milk protein products. *Breastfeed Med* 2014;9:281–5.
- [42] Ziegler EE. II. Advantages of human milk in feeding premature infants. *J Pediatr Gastroenterol Nutr* 2015;61(Suppl. 1):S3.
- [43] Calbet JA, MacLean DA. Plasma glucagon and insulin responses depend on the rate of appearance of amino acids after ingestion of different protein solutions in humans. *J Nutr* 2002;132:2174–82.
- [44] Andorsky DJ, Lund DP, Lillehei CW, et al. Nutritional and other postoperative management of neonates with short bowel syndrome correlates with clinical outcomes. *J Pediatr* 2001;139:27–33.
- [45] Almaas AN, Tamnes CK, Nakstad B, et al. Long-chain polyunsaturated fatty acids and cognition in VLBW infants at 8 years: an RCT. *Pediatrics* 2015;135:972–80.
- [46] Mok E, Hankard R. Glutamine supplementation in sick children: is it beneficial? *J Nutr Metab* 2011;2011:617597.
- [47] Reddy VS, Patole SK, Rao S. Role of probiotics in short bowel syndrome in infants and children – a systematic review. *Nutrients* 2013;5:679–99.
- [48] Gibson GR, Probert HM, Loo JV, Rastall RA, Roberfroid MB. Dietary modulation of the human colonic microbiota: updating the concept of prebiotics. *Nutr Res Rev* 2004;17:259–75.
- [49] Mezzoff EA, Hawkins JA, Ollberding NJ, Karns R, Morrow AL, Helmrath MA. The human milk oligosaccharide 2'-fucosyllactose augments the adaptive response to extensive intestinal. *Am J Physiol Gastrointest Liver Physiol* 2016;310:G427–38.
- [50] Pammi M, Abrams SA. Oral lactoferrin for the prevention of sepsis and necrotizing enterocolitis in preterm infants. *Cochrane Database Syst Rev* 2015;(2):CD007137.
- [51] Yang Q, Welch CD, Ayers K, Turner C, Prankoff T. Early enteral fat supplementation with microlipid® and fish oil in the treatment of two premature infants with short bowel. *Neonatology* 2010;98:348–53.
- [52] Yang Q, Ayers K, Welch CD, O'Shea TM. Randomized controlled trial of early enteral fat supplement and fish oil to promote intestinal adaptation in premature infants with an enterostomy. *J Pediatr* 2014;165:274–9. e271.
- [53] Yang Q, Ayers K, Chen Y, O'Shea TM. Early enteral fat supplementation improves protein absorption in premature infants with an enterostomy. *Neonatology* 2014;106:10–6.
- [54] Tillman EM, Crill CM, Black DD, et al. Enteral fish oil for treatment of parenteral nutrition-associated liver disease in six infants with short-bowel syndrome. *Pharmacotherapy* 2011;31:503–9.
- [55] Pieroni KP, Nespor C, Ng M, et al. Evaluation of ethanol lock therapy in pediatric patients on long-term parenteral nutrition. *Nutr Clin Pract* 2013;28:226–31.
- [56] Ng PC. Use of oral erythromycin for the treatment of gastrointestinal dysmotility in preterm infants. *Neonatology* 2009;95:97–104.
- [57] Schwartz MZ. Novel therapies for the management of short bowel syndrome in children. *Pediatr Surg Int* 2013;29:967–74.
- [58] Jeppesen PB, Pertkiewicz M, Messing B, et al. Teduglutide reduces need for parenteral support among patients with short bowel syndrome with intestinal failure. *Gastroenterology* 2012;143:1473–81. e1473.
- [59] Jeppesen PB, O'Keefe S, Chu H, Joelsson B. Short bowel syndrome patients with intestinal failure (SBS-IF) successfully achieved complete independence from parenteral nutrition and/or intravenous fluid (PN/IV) with teduglutide. *Gastroenterology* 2012;142:S369–70.
- [60] Sigalet DL, Martin GR, Butzner JD, Buret A, Meddings JB. A pilot study of the use of epidermal growth factor in pediatric short bowel syndrome. *J Pediatr Surg* 2005;40:763–8.
- [61] Peretti N, Loras-Duclaux I, Kassai B, et al. Growth hormone to improve short bowel syndrome intestinal autonomy: a pediatric randomized open-label clinical trial. *J Parenter Enteral Nutr* 2011;35:723–31.
- [62] Peterson J, Kerner JA. New advances in the management of children with intestinal failure. *J Parenter Enteral Nutr* 2012;36(1 Suppl):365–42S.
- [63] Rhoads JM, Plunkett E, Galanko J, et al. Serum citrulline levels correlate with enteral tolerance and bowel length in infants with short bowel syndrome. *J Pediatr* 2005;146:542–7.
- [64] Fitzgibbons S, Ching YA, Valim C, et al. Relationship between serum citrulline levels and progression to parenteral nutrition independence in children with short bowel syndrome. *J Pediatr Surg* 2009;44:928–32.
- [65] Ladd MR, Niño DF, March JC, Sodhi CP, Hackam DJ. Generation of an artificial intestine for the management of short bowel syndrome. *Curr Opin Organ Transplant* 2016;21:178–85.